

One-stage laparoscopic bisegmentectomy 7–8 and bisegmentectomy 2–3 for bilateral colorectal liver metastases

Marcel Autran C. Machado · F. A. Almeida ·
F. F. Makdissi · R. C. Surjan · G. A. Cunha-Filho

Received: 26 January 2010 / Accepted: 5 October 2010
© Springer Science+Business Media, LLC 2010

Abstract

Background Bisegmentectomy 7–8 is feasible even in the absence of a large inferior right hepatic vein. To our knowledge, this operation has never been performed by laparoscopy. This study was designed to present video of pure laparoscopic bisegmentectomy 7–8 and bisegmentectomy 2–3 in one-stage operation for bilateral liver metastasis.

Methods A 67-year-old man with metachronous bilobar colorectal liver metastasis was referred for surgical treatment after neoadjuvant chemotherapy. CT scan disclosed two liver metastases: one located between segments 7 and 8 and another one in segment 2. At liver examination, another metastasis was found on segment 3. We decided to perform a bisegmentectomy 7–8 along with bisegmentectomy 2–3 in a single procedure. The operation began with mobilization of the right liver with complete dissection of retrohepatic vena cava. Inferior right hepatic vein was absent. Right hepatic vein was dissected and encircled. Upper part of right liver, containing segment 7 and 8, was marked with cautery. Selective hemi-Pringle maneuver was performed and right hepatic vein was divided with stapler. At this point, liver rotation to the left allowed direct view and access to the superior aspect of the right liver. Liver transection was accomplished with harmonic scalpel and

endoscopic stapling device. Bisegmentectomy 2–3 was performed using the intrahepatic Glissonian approach. The specimens were extracted through a suprapubic incision. Liver raw surfaces were reviewed for bleeding and bile leaks.

Results Operative time was 240 minutes with no need for transfusion. Recovery was uneventful. Patient was discharged on the fifth postoperative day. Patient is well with no evidence of disease 14 months after liver resection. Tumor markers are within normal range.

Conclusions Bisegmentectomy 7–8 may increase resectability rate in patients with bilateral lesions. This operation can be performed safely by laparoscopy. Preservation of segments 5 and 6 permitted simultaneous resection of segments 2 and 3 with adequate liver remnant.

Keywords Liver · Laparoscopy · Technique · Bisegmentectomy 7-8 · Colorectal metastasis

Liver resection prolongs survival time of patients with colorectal liver metastases [1]. Preservation of liver parenchyma should always be attempted to prevent postoperative liver failure and to increase the opportunity to perform resections in cases of recurrent or bilateral malignancy.

Until recently, according to some authors [2, 3], bisegmentectomy 7-8 should only be attempted if a large accessory right inferior hepatic vein was present, and this operation was rarely performed. However, based on anatomic studies, we reported the feasibility and safety of this operation even in the absence of this accessory vein [4].

Recent advances in laparoscopic devices and experience with advanced techniques have increased the indications for laparoscopic liver resection [5]. This video demonstrates

Electronic supplementary material The online version of this article (doi:10.1007/s00464-010-1503-2) contains supplementary material, which is available to authorized users.

M. A. C. Machado (✉) · F. A. Almeida · F. F. Makdissi ·
R. C. Surjan · G. A. Cunha-Filho
Department of Gastroenterology, University of São
Paulo, Rua Evangelista Rodrigues 407,
São Paulo 05463-000, Brazil
e-mail: dr@drmarcel.com.br

technical aspects of a pure laparoscopic bisegmentectomy 7–8 and bisegmentectomy 2–3 in a one-stage operation for bilateral liver metastasis. To our knowledge, hepatic bisegmentectomy 7–8 has never been performed by laparoscopy in the English literature.

Patients and methods

A 67-year-old man suffering from metachronous bilobar colorectal liver metastasis was referred for surgical treatment after neoadjuvant chemotherapy. CT scan and MRI disclosed two liver metastases: one located between segments 7 and 8 (Fig. 1A) and another one in segment 2 (Fig. 1B). Surgical decision was to perform a totally laparoscopic liver resection.

The patient is placed in a left semilateral decubitus position with the surgeon standing between the patient's legs. This technique uses five trocars. Type and location of trocars have been described elsewhere [6]. Pneumoperitoneum is established at a pressure of 12 mmHg.

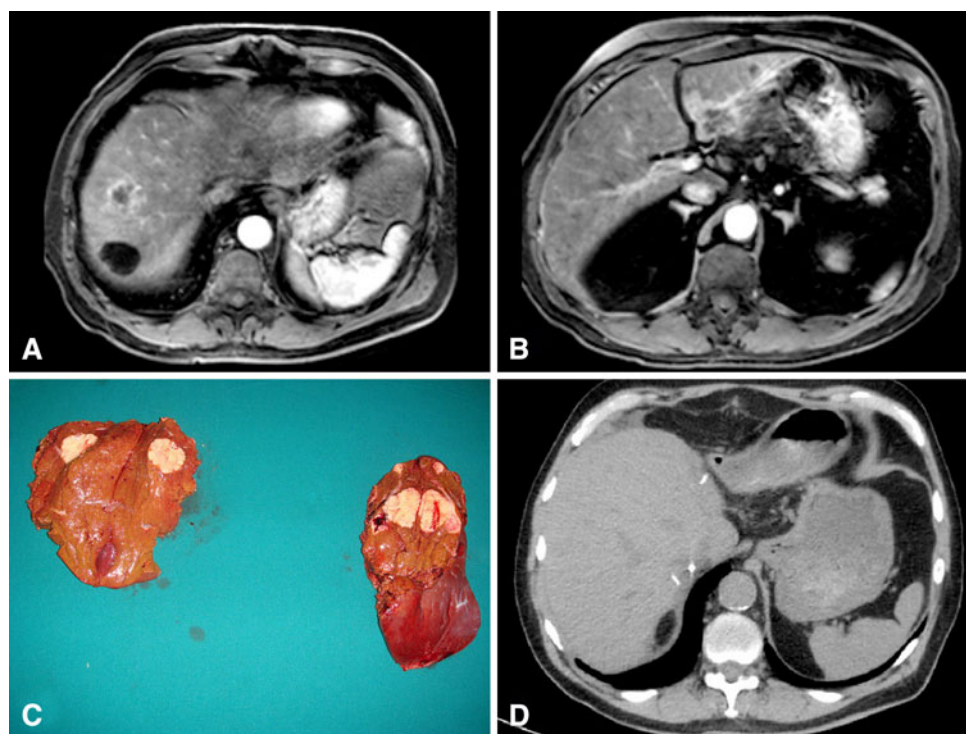
At laparoscopy, during liver examination another metastasis was found on the surface of segment 3. We decided to perform a bisegmentectomy 7–8 along with bisegmentectomy 2–3 in a single procedure. The operation began with mobilization of the right liver with complete dissection of retrohepatic vena cava. Inferior right hepatic vein was absent. Right hepatic vein was dissected and encircled. The upper part of the right liver, containing

segments 7 and 8, was marked with cautery. Selective hemi-Pringle maneuver [7] was performed and right hepatic vein was divided with stapler (Ethicon EndoSurgery Industries, Cincinnati, OH). At this point, liver rotation to the left allowed direct view and access to the superior aspect of the right liver. Liver transection was accomplished with harmonic scalpel and endoscopic stapling device. Bisegmentectomy 2–3 was performed using intrahepatic Glissonian approach without Pringle maneuver and without hilar dissection as previously described by the authors [8]. Intrahepatic access to liver segments 2 and 3 pedicle was achieved with two small incisions and an endoscopic vascular stapling device was inserted between these incisions and the stapler fired. The line of liver transection was marked along the liver surface following the ischemic area. Liver transection was accomplished with harmonic scalpel and endoscopic stapling device as appropriate (Ethicon EndoSurgery Industries). The specimens were extracted through a suprapubic incision (Fig. 1C). Liver raw surfaces were reviewed for bleeding and bile leaks, and one round 19F Blake abdominal drain (Ethicon, Inc., Cincinnati, OH) was left in place.

Results

Operative time was 240 min with minimum blood loss and no need for blood transfusion. Recovery was uneventful and the patient was discharged on the fifth postoperative day.

Fig. 1 Laparoscopic bisegmentectomy 7–8 and bisegmentectomy 2–3 for bilateral colorectal liver metastases. **A** Preoperative MRI. Liver metastasis between segments 7 and 8. Note a large simple cyst in segment 7. **B** Preoperative MRI. Liver metastasis in segment 2. **C** On the left, surgical specimen from bisegmentectomy 7–8: one metastasis with clear surgical margins. On the right, surgical specimen from bisegmentectomy 2–3 shows two lesions, one superficial. Surgical margins are free. **D** Postoperative CT scan shows adequate regeneration of liver remnant



The abdominal drain did not show any sign of bile leak or and it was removed on the eighth postoperative day. Histological examination revealed clear surgical margins. Postoperative CT scan showed good regeneration of segments 5 and 6 despite absence of main and inferior right hepatic veins (Fig. 1D). Patient is well and with no evidence of disease 14 months after liver resection, during oncologic follow-up. Tumor markers are within normal range.

Discussion

Modern laparoscopic devices and experience with advanced techniques have increased the indications for laparoscopic liver resection. Several studies have demonstrated the safety and feasibility of laparoscopy for minor and major liver resections [5–8]. According to an extensive world review of almost 3,000 cases, laparoscopic liver resections are safe with acceptable morbidity and mortality for both minor and major hepatic resections. Oncologically, 3- and 5-year survival rates reported for colorectal cancer metastases are comparable to open hepatic resection [9]. Moreover, a recently published multi-institutional series has shown that laparoscopic liver resection for colorectal metastasis is safe, feasible, and oncologically comparable to open liver resection for both minor and major liver resections, even with prior intra-abdominal operations, in selected patients and when performed by experienced surgeons [10]. Comparative study has shown that laparoscopy is associated with less bleeding, fewer complications, and a better quality of life than open liver surgery [11]. Other potential advantages include decreased analgesic requirements, less adhesions, fast recovery, and preservation of immune function. Burpee et al. [12] suggested that laparoscopic liver resection results in a diminished stress response, which may translate into greater preservation of immune function with a beneficial effect on infection and tumor growth. Faster recovery may allow for earlier administration of adjuvant chemotherapy—an important issue for colorectal liver metastasis.

Preservation of liver parenchyma should always be attempted to prevent postoperative liver failure and to increase the opportunity to perform repeated resections in cases of recurrent malignancy. For bilateral metastatic liver disease, we always attempt to resect all liver lesions in a single procedure. However, for extremely difficult cases of bilateral metastatic liver disease, this strategy is replaced by two-stage liver resection. Generally, open procedure is advised for this treatment option; however, we have successfully used laparoscopy for two-stage liver resection in selected cases [13].

Bisegmentectomy 7–8 involves the division of the main right hepatic vein and the ancient concept that the

remaining right liver (segments 5 and 6) would lack venous drainage if a large inferior right hepatic vein is not present made this operation an exception until few years ago. In 2006, we reported the feasibility of this challenging procedure, even in the absence of a large accessory inferior hepatic vein in four consecutive patients [4]. Capussotti et al. reported an elegant color-Doppler intraoperative ultrasound study to evaluate the vascular pattern of the remaining segment 6 and reached to the same conclusion about the feasibility of this procedure [14].

Experience with right lobe living donor liver transplantation has shown that venous drainage from anterior segments substantially depends on tributaries of the middle hepatic vein, indicating that middle hepatic vein can provide adequate venous drainage for the remnant right liver after bi-segmentectomy 7–8 and ligation of right hepatic vein [15].

Bisegmentectomy 7–8 may increase the resectability rate in patients with bilateral lesions. Indeed, laparoscopic resection of segments 7 and 8 in the present case was essential to permit removal of all liver metastases in one stage, leaving an adequate future liver remnant. Laparoscopic bisegmentectomy 7–8 did not result in outflow block in the absence of a large inferior right hepatic vein. Intraoperative aspect of both segments 5 and 6 was normal. Postoperative CT scan confirmed adequate regeneration of these segments along the remaining liver (Fig. 1D).

Laparoscopic hepatic bisegmentectomy 7–8 is technically demanding and may require both laparoscopic and liver surgery expertise.

Conclusions

Bisegmentectomy 7–8 may increase resectability rate in patients with bilateral lesions. This operation can safely be done by laparoscopy. Preservation of segments 5 and 6 permitted simultaneous resection of segments 2 and 3 with adequate liver remnant and excellent immediate result.

Disclosures Drs. Machado, Almeida, Makdissi, Surjan, and Cunha-Filho have no conflicts of interest or financial ties to disclose.

References

1. Fong Y, Fortner J, Sun RL, Brennan MF, Blumgart LH (1999) Clinical score for predicting recurrence after hepatic resection for metastatic colorectal cancer: analysis of 1001 consecutive cases. *Ann Surg* 230:309–318
2. Hamy A, d'Alincourt A, Floch I, Madoz A, Paineau J, Lerat F (2004) Bisegmentectomy 7–8: importance of preoperative diagnosis of a right inferior hepatic vein. *Ann Chir* 129:282–285

3. Muratore A, Conti P, Amisano M, Bouzari H, Capussotti L (2005) Bisegmentectomy 7–8 as alternative to more extensive liver resections. *J Am Coll Surg* 200:224–228
4. Machado MA, Herman P, Makdissi FF, Figueira ER, Bacchella T, Machado MC (2006) Feasibility of bisegmentectomy 7–8 is independent of the presence of a large inferior right hepatic vein. *J Surg Oncol* 15(93):338–342
5. Koffron AJ, Auffenberg G, Kung R, Abecassis M (2007) Evaluation of 300 minimally invasive liver resections at a single institution: less is more. *Ann Surg* 246:385–392
6. Machado MA, Makdissi FF, Bacchella T, Machado MC (2005) Hemihepatic ischemia for laparoscopic liver resection. *Surg Laparosc Endosc Percutan Tech* 15:180–183
7. Machado MA, Makdissi FF, Galvão FH, Machado MC (2008) Intrahepatic Glissonian approach for laparoscopic right segmental liver resections. *Am J Surg* 196:e38–e42
8. Machado MA, Makdissi FF, Surjan RC, Herman P, Teixeira AR, Machado MC (2009) Laparoscopic resection of left liver segments using the intrahepatic Glissonian approach. *Surg Endosc* 23:2615–2619
9. Nguyen KT, Gamblin TC, Geller DA (2009) World review of laparoscopic liver resection-2, 804 patients. *Ann Surg* 250: 831–834
10. Castaing D, Vibert E, Ricca L, Azoulay D, Adam R, Gayet B (2009) Oncologic results of laparoscopic versus open hepatectomy for colorectal liver metastases in two specialized centers. *Ann Surg* 250:849–855
11. Dagher I, Giuro GD, Dubrez J, Lainas P, Smadja C, Franco D (2009) Laparoscopic versus open right hepatectomy: a comparative study. *Am J Surg* 198:173–177
12. Burpee SE, Kurian M, Murakame Y et al (2002) The metabolic and immune response to laparoscopic versus open liver resection. *Surg Endosc* 16:899–904
13. Machado MA, Makdissi FF, Surjan RC, Kappaz GT, Yamaguchi N (2010) Two-stage laparoscopic liver resection for bilateral colorectal liver metastasis. *Surg Endosc* 24:2044–2047
14. Capussotti L, Ferrero A, Vigano L, Polastri R, Ribero D, Berrino E (2006) Hepatic bisegmentectomy 7–8 for a colorectal metastasis. *Eur J Surg Oncol* 32:469–471
15. Kaneko T, Sugimoto H, Hirota M, Kure S, Kiuchi T, Nakao A (2005) Intrahepatic venous anastomosis formation of the right liver in living donor liver transplantation: evaluations by Doppler ultrasonography and pulse-inversion ultrasonography with Levovist. *Surgery* 138:21–27